Journal of Clinical and Nursing Research, 2026, Volume 10, Issue 9
https://bbwpublisher.com/journal/JCNR
Online ISSN: 2208-3693
Print ISSN: 2208-3685

Clinical Implementation of Regional Citrate Anticoagulation in Combined CRRT and ECCO$_2$R Therapy: A Case Report

Qiongxing Bu[1,2]†, Yuejun Liu[1,3]†, Wei Yang[4]†, Zhifeng Zhou[1], Ling Zhang[1]*

[1]Department of Nephrology, Kidney Research Institute, West China Hospital of Sichuan University, Chengdu 610041, Sichuan, China
[2]Department of Nephrology, Heping Hospital Affiliated to Changzhi Medical College, Changzhi 046000, Shanxi, China
[3]Department of Nephrology, Huize County People's Hospital, Qujin 655000, Yunnan, China
[4]Department of Nephrology, Shanxi Provincial Hospital of Traditional Chinese Medicine, Taiyuan 030000, Shanxi, China
† These authors contributed equally to this work and share the first authorship.

***Corresponding author**:* Ling Zhang, zhangling_crrt@163.com

Copyright: © 2026 Author(s). This is an open-access article distributed under the terms of the Creative Commons Attribution License (CC BY 4.0), permitting distribution and reproduction in any medium, provided the original work is cited.

Abstract: *Background*: Hypercapnia is a common precipitating factor for multiple organ failure in critically ill patients. The combination of continuous renal replacement therapy (CRRT) and extracorporeal carbon dioxide removal (ECCO$_2$R) represents a targeted pulmonary-renal support strategy; however, anticoagulation management during prolonged treatment remains a clinical challenge. Traditional unfractionated heparin carries risks of bleeding or circuit clotting, while evidence for regional citrate anticoagulation (RCA) in CRRT-ECCO2R combination therapy remains limited, with practical data in high-flow settings particularly lacking. This case report describes a novel anticoagulation regimen combining low molecular weight heparin (LMWH) and 4% citrate, providing a practical alternative for anticoagulation management in this complex therapy. *Case presentation*: A 59-year-old male patient with over a decade of occupational dust exposure (cement plant, gold mine, coal mine) and a history of pulmonary tuberculosis presented with cough, sputum production, and dyspnoea. On admission, oxygen saturation was 30–40%, arterial partial pressure of carbon dioxide ($PaCO_2$) was 142.33 mmHg, and serum potassium was 6.13 mmol/L. Diagnoses included acute exacerbation of chronic obstructive pulmonary disease (AECOPD), sepsis, septic shock, Legionella pneumonia, pulmonary encephalopathy, type II respiratory failure, and acute respiratory distress syndrome (ARDS). Despite initial management with antimicrobial therapy, fluid resuscitation, and mechanical ventilation, persistent hypercapnia ($PaCO_2$ > 100 mmHg) and hyperkalaemia persisted. Combined CRRT-ECCO$_2$R therapy was initiated from 23 May to 5 June 2025 (total 197 cumulative hours), with blood flow rate 300 mL/min, oxygen flow rate 8–10 L/min. Anticoagulation comprised LMWH (2000 U loading dose + 200 U/h continuous infusion), 4% trisodium citrate (200–210 mL/min), and 10% calcium gluconate (2–5 mL/h). After treatment, the patient showed significant reduction in $PaCO_2$, restored pH, improved oxygenation, no clinically significant bleeding events, and stable haemoglobin levels. However, due to financial constraints, the patient was transferred to a local healthcare facility for further care. *Conclusion*: In CRRT-ECCO$_2$R combined therapy, the LMWH + 4% citrate anticoagulation regimen effectively maintained circuit patency

(mean lifespan 65.67 hours) at a high flow rate of 300 mL/min, achieved efficient carbon dioxide clearance (mean clearance rate 44.5 mL/min), rapidly corrected acid-base imbalance, and demonstrated good safety. This approach overcomes limitations of conventional anticoagulation, offering a novel therapeutic option for critically ill hypercapnic patients at bleeding risk, with promising clinical utility and cost-effectiveness.

Keywords: Continuous renal replacement therapy (CRRT); Extracorporeal carbon dioxide removal ($ECCO_2R$); Regional citrate anticoagulation (RCA); Low molecular weight heparin (LMWH)

Online publication: October 23, 2026

1. Introduction

Hypercapnia is defined as arterial partial pressure of carbon dioxide ($PaCO_2$) exceeding 45 mmHg. It most commonly arises from upper airway obstruction, chronic obstructive pulmonary disease (COPD), thoracic and pleural disorders, or respiratory centre-depressant medications. Hypercapnia can reduce myocardial contractility, induce vasodilation, and increase cerebral blood flow, potentially causing impaired consciousness in severe cases. Although permissive hypercapnia is sometimes employed to reduce ventilator-induced lung injury (VILI), persistent severe hypercapnia remains a major driver of multiorgan dysfunction in critically ill patients [1].

To minimize VILI, improve respiratory failure, shorten mechanical ventilation duration, and facilitate early extubation, the combination of CRRT and $ECCO_2R$ has emerged as a targeted lung-kidney support strategy [2]. CRRT-$ECCO_2R$ employs two circuit configurations: arteriovenous (V-A) and venovenous (V-V), with the V-V configuration generally preferred as it maintains arterial integrity while offering superior haemodynamic stability [3,4]. Compared to venovenous extracorporeal membrane oxygenation (VV-ECMO), ECCO2R offers a lower technical threshold, less haemodynamic impact, reduced vascular injury, smaller catheter size, and lower cost, making it an attractive option for centres without advanced ECMO capabilities [5–7].

Animal studies have validated the efficacy of $ECCO_2R$ in controlling hypercapnia. Godet et al. using an infant-sized oxygenator in hypercapnic porcine models showed that CO_2 clearance ranged from 35 to 75 mL/min, with clearance maintained even at the lowest blood flow rates regardless of oxygen flow [8]. Christian et al. demonstrated that with modern low-flow oxygenators, post-membrane PCO_2 could be controlled within 10–25 mmHg when oxygen flow rate was ≥ 6 L/min [9].

Long-term $ECCO_2R$ and CRRT require rigorous anticoagulation management. Early studies predominantly used unfractionated heparin (UFH), but regional citrate anticoagulation (RCA) is now recommended for its reduced bleeding risk and extended filter lifespan [4,9–15]. However, the 2023 review by Tonetti et al. noted that heparin and argatroban remain common options for extracorporeal life support (ECLS), each with drawbacks and unresolved issues [16]. Importantly, no literature has reported the application of RCA in ECLS in high-flow settings. The KDIGO guidelines and some authors caution against RCA use in patients with hypotension, hypoxaemia, or severe liver disease—conditions that are not uncommon in $ECCO_2R$ candidates [17,18].

In this case report, we describe the use of a combined LMWH + 4% citrate anticoagulation regimen in a critically ill patient undergoing CRRT-$ECCO_2R$ therapy. This protocol was implemented after multidisciplinary assessment by the CRRT team at West China Hospital of Sichuan University, with informed consent obtained from the patient's family.

2. Patient information

A 59-year-old male patient presented with a chief complaint of intermittent cough with sputum production persisting for over a decade. He sought local hospital care within the past two months due to worsening dyspnoea. Tracheal intubation was performed and anti-infective therapy initiated owing to persistent desaturation (30–40%) and hypercapnia ($PaCO_2$ 115 mmHg). Post-intervention arterial blood gas analysis continued to demonstrate carbon dioxide retention, prompting transfer to our hospital's Emergency Department for further management. Past medical history includes occupational exposure to cement plants, gold mines, and coal mines (> 10 years), alongside a history of pulmonary tuberculosis treated with unspecified anti-tuberculosis therapy.

Emergency admission vital signs: Temperature 36.4 °C, blood pressure 93/59 mmHg, respiratory rate 20 breaths/min, pulse rate 114 beats/min, oxygen saturation 98%. The patient appeared lethargic, remained intubated, exhibited coarse breath sounds, bilateral moist rales, and no significant abdominal abnormalities.

Key investigations (Huaxi Hospital Emergency Department, 20 May 2025): Chest CT revealed scattered patchy opacities, linear atelectasis, nodular densification, and confluent consolidation predominantly involving the upper lobes. Biomarkers: Procalcitonin 1.77 ng/mL, C-reactive protein 88.4 mg/L, interleukin-6 165.3 pg/mL, Legionella IgG/IgM antibodies positive.

Diagnosis: 1. Acute exacerbation of chronic obstructive pulmonary disease (AECOPD); 2. Sepsis (per SOFA criteria); 3. Septic shock; 4. Severe pneumonia (Legionella); 5. Pulmonary encephalopathy; 6. Type II respiratory failure; 7. Acute respiratory distress syndrome (ARDS).

Initial management: RASS score -3; maintained sedation/analgesia (propofol 150mg, 0.05mg/kg/h + midazolam 50mg, 0.06mg/kg/h + remifentanil 2mg, 0.3mg/kg/h IV infusion). Vasopressor support included: 32mg noradrenaline in 5% glucose solution (total 50mL) infused at 1-2μg/kg/min; 12U vasopressin in normal saline (total 48mL) infused intravenously at 3mL/h. Mechanical ventilation (A/C-PRVC mode): respiratory rate 30 breaths/min, tidal volume 380–400 mL, positive end-expiratory pressure 5–8 cm H_2O, inspired oxygen concentration 60–70%. Anti-infective therapy: Meropenem 1 g every 8 hours. Adjunctive therapy included ambroxol/salbutamol for bronchodilation/mucus clearance, enteral nutrition, and intravenous immunoglobulin for immunomodulation.

Clinical progression: On 23 May 2025, combined continuous renal replacement therapy (CRRT) with extracorporeal carbon dioxide removal ($ECCO_2R$) was initiated due to refractory hypercapnia ($PaCO_2$ > 100 mmHg) and hyperkalaemia (K^+ 6.0–7.0 mmol/L). CRRT (Baxter Gambro machine/prismaflex, Gambro circuitry) employed post-dilution calcium-containing haemofiltration (prescribed rate 2 L/h; replacement fluid: dialysate = 1:1). $ECCO_2R$ (Xijian ECMO system, infant membrane oxygenator, surface area 0.5m²) was initiated via a right femoral vein-placed Bard® dialysis catheter (National Medical Device Registration Certificate No.: 20183101940), with oxygen flow rate 8–10 L/min. Anticoagulation therapy: Low molecular weight heparin (LMWH) initial loading dose 2000 U, followed by continuous intravenous infusion at 200 U/h; regional citrate anticoagulation (4% trisodium citrate 200–210 mL/min; 10% calcium gluconate 2–5 mL/h). The $ECCO_2R$ circuit membrane was replaced three times during the 9-day treatment period. Outcome: Arterial blood gas analysis demonstrated significant reduction in $PaCO_2$, improved oxygenation, and restoration of pH to normal levels. However, owing to financial constraints and poor prognosis, the patient was discharged against medical advice to a local healthcare facility.

3. Results

3.1. Carbon dioxide clearance

Carbon dioxide clearance ($^{\Delta}PCO_2$) was calculated using the following formula: $^{\Delta}PCO_2$ = (PCO_2 pre-filtration

- PCO_2 post-filtration) × blood flow rate (mL/min) [9]. The mean PCO_2 clearance rate (total $^{\Delta}PCO_2$ divided by total minutes) was 44.5 mL/min (526,294.8 mmHg·mL / (197 hours × 60 min/hour). Mean $PaCO_2$ reduction was 51.2 mmHg, mean pH increased by 0.32, and mean circuit lifespan was 65.67 hours. **Figure 1** illustrates the trends in pre- and post-filtration PCO_2 and pH values during the combined therapy.

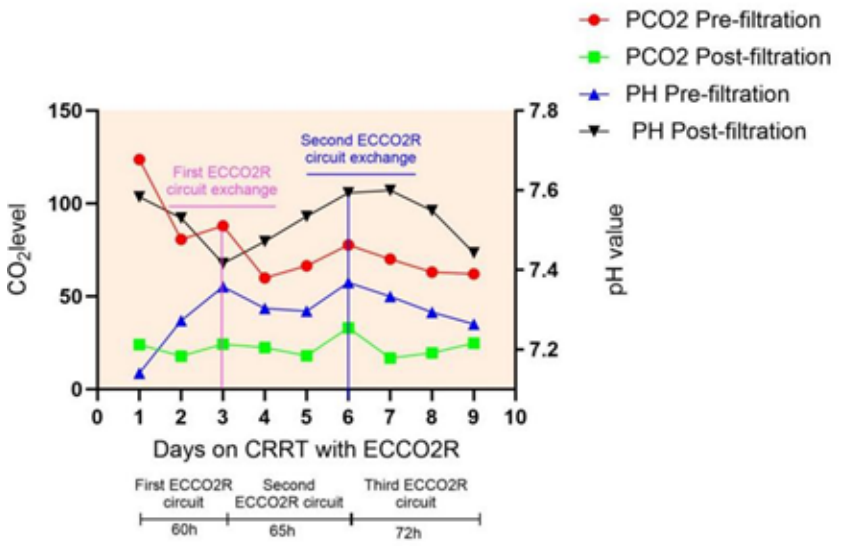

Figure 1. Trends in pre- and post-filtration PCO2 and pH values during the combined therapy.

3.2. Oxygenation improvement

The mean increase in PO_2 was 428.52 mmHg (95% confidence interval: 402.1–454.9). **Figure 2** shows the trend in pre- and post-filtration PO.

Ionised calcium monitoring:

The mean Pre-filtration ionised calcium (Ca^{2+}) was 1.08 mmol/L (SD ± 0.12), and post-filtration Ca^{2+} was 0.48 mmol/L (SD ± 0.07). **Figure 3** shows the trends during therapy.

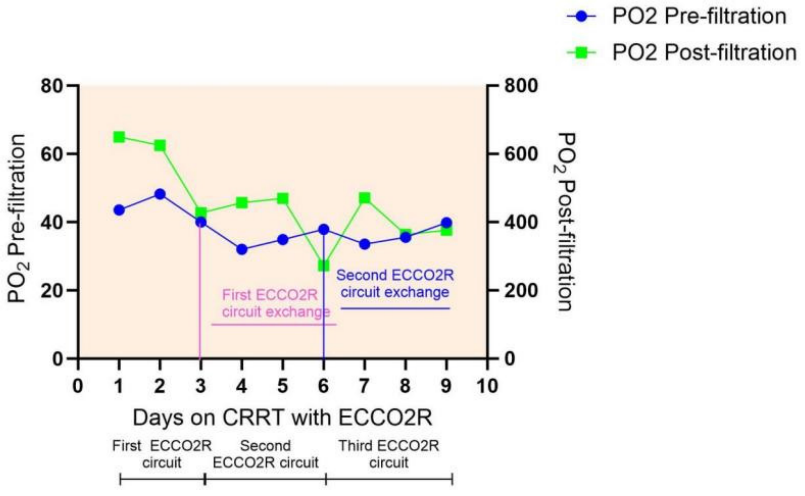

Figure 2. Trend in pre- and post-filtration PO_2 during combined therapy.

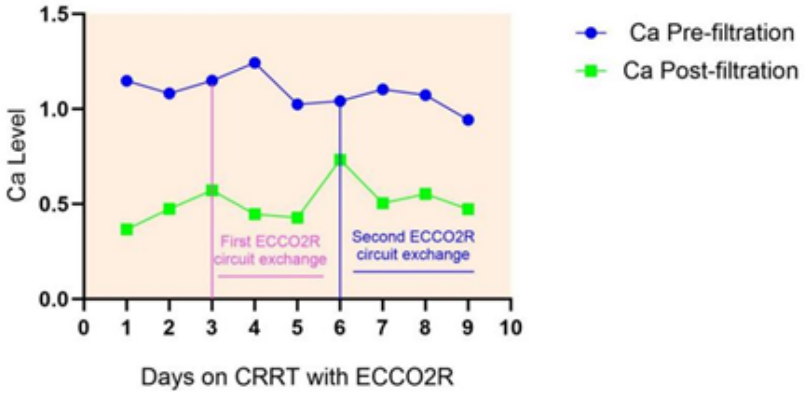

Figure 3. Trends in pre- and post-filtration ionized calcium levels during combined therapy.

Table 1. Pre-filtration blood gas analysis during combined CRRT-ECCO₂R therapy (daily measurements)

Days	Time	Blood gas analysis	PH Mean ± SD	PO_2 Mean ± SD	PCO_2 Mean ± SD	Be Mean ± SD	Ca Mean ± SD	Lac Mean ± SD	Circuit Configuration	Anticoagulation Protocol	Blood flow rate
1	2025-05-23 05:02:01.000	Pre-filtration VBG	7.14 ± 0.05	43.55 ± 23.8	123.66 ± 18.73	10.09 ± 1.5	1.15 ± 0.09	3.06 ± 0.88	Standard calcium reinfusion	LMWH + RCA	300
2	2025-05-24 03:28:43.000	Pre-filtration VBG	7.27 ± 0.08	48.22 ± 14.67	80.66 ± 14.26	7.85 ± 1.24	1.08 ± 0.07	2.46 ± 0.57	Standard calcium reinfusion	LMWH + RCA	300
3	2025-05-25 04:37:36.000	Pre-filtration VBG	7.36 ± 0.04	40.03 ± 8.01	70.9 ± 5.14	11.97 ± 1.22	1.15 ± 0.05	1.83 ± 0.29	Standard calcium reinfusion	LMWH + RCA	300
4	2025-05-31 04:28:20.000	Pre-filtration VBG	7.3 ± 0.02	32.02 ± 1.52	59.89 ± 2.5	2.21 ± 1.34	1.24 ± 0.17	1.42 ± 0.3	Standard calcium reinfusion	LMWH + RCA	300
5	2025-06-01 04:59:10.000	Pre-filtration VBG	7.3 ± 0.03	34.9 ± 2.73	66.46 ± 1.93	4.46 ± 2.47	1.02 ± 0.04	1.55 ± 0.08	Standard calcium reinfusion	LMWH + RCA	300
6	2025-06-02 04:20:15.000	Pre-filtration VBG	7.37 ± 0.01	37.91 ± 3.82	62.74 ± 0.84	8.91 ± 0.71	1.04 ± 0.02	1.62 ± 0.34	Standard calcium reinfusion	LMWH + RCA	300
7	2025-06-03 00:04:10.000	Pre-filtration VBG	7.33 ± 0.02	33.56 ± 2.42	70.06 ± 4.14	9.04 ± 0.46	1.1 ± 0.03	2.05 ± 0.5	Standard calcium reinfusion	LMWH + RCA	300
8	2025-06-04 04:13:31.000	Pre-filtration VBG	7.29 ± 0.04	35.59 ± 4.48	63.1 ± 3.23	2.61 ± 2.82	1.07 ± 0.03	2.44 ± 0.53	Standard calcium reinfusion	LMWH + RCA	300
9	2025-06-05 04:02:02.000	Pre-filtration VBG	7.26 ± 0.02	39.83 ± 0.3	62.02 ± 1	-0.15 ± 1.96	0.94 ± 0.1	2.5 ± 0.79	Standard calcium reinfusion	LMWH + RCA	300

Table 2. Post-filter blood gas analysis during combined CRRT-ECCO₂R therapy (daily measurements)

Days	**Time**	**Blood gas analysis**	**PH Mean ± SD**	**PO_2 Mean ± SD**	**PCO_2 Mean ± SD**	**Be Mean ± SD**	**Ca Mean ± SD**	**Lac Mean ± SD**
1	2025-05-23 07:29:39.000	Post-filtration VBG	7.58 ± 0.02	649.97 ± 56.79	24.08 ± 2.07	0.85 ± 1.42	0.37 ± 0.08	2.65 ± 0.94

2	2025-05-24 03:57:01.000	Post-filtration VBG	7.73 ± 0.08	624.86 ± 106.26	17.82 ± 2.25	3.84 ± 2.99	0.47 ± 0.03	2.51 ± 0.2
3	2025-05-25 04:19:58.000	Post-filtration VBG	7.72 ± 0.07	427.32 ± 27.3	21.3 ± 2.51	6.55 ± 2.39	0.57 ± 0.04	1.78 ± 0.21
4	2025-05-31 04:34:35.000	Post-filtration VBG	7.57 ± 0.08	457.3 ± 91.42	22.45 ± 6.75	-1.77 ± 1.77	0.85 ± 0.32	1.51 ± 0.28
5	2025-06-01 05:07:19.000	Post-filtration VBG	7.53 ± 0.23	272.46 ± 190.27	33.12 ± 17.29	-0.72 ± 1	0.43 ± 0.13	1.59 ± 0.19
6	2025-06-02 04:25:16.000	Post-filtration VBG	7.69 ± 0.05	469.23 ± 95.44	18.08 ± 2.91	1.72 ± 0.18	0.47 ± 0.02	1.61 ± 0.18
7	2025-06-03 00:07:09.000	Post-filtration VBG	7.7 ± 0.02	470.86 ± 86.11	16.84 ± 0.52	1.36 ± 0.54	0.5 ± 0.02	1.94 ± 0.39
8	2025-06-04 04:16:21.000	Post-filtration VBG	7.55 ± 0.06	363.76 ± 62.37	19.57 ± 1.06	-4.26 ± 2.35	0.55 ± 0.06	2.55 ± 0.63
9	2025-06-05 03:59:10.000	Post-filtration VBG	7.44 ± 0.06	376.53 ± 48.54	24.83 ± 2.31	-6.32 ± 1.59	0.47 ± 0.06	2.38 ± 0.5

4. Discussion

$ECCO_2R$ is an evolution of ECMO that operates by connecting a membrane oxygenator to a blood pump. Compared to VV-ECMO, $ECCO_2R$ achieves equivalent CO_2 removal at markedly lower blood flow rates (0.5–1.5 L/min vs. 3–7 L/min), reducing haemodynamic impact, vascular injury, and cost [7]. Combining $ECCO_2R$ with CRRT is therefore a practical, cost-effective multi-organ support option.

Based on prior findings that with oxygen flow ≥ 6 L/min, post-membrane PCO_2 can be controlled within 10–25 mmHg, we used an infant-sized oxygenator with blood flow 300 mL/min and oxygen flow 8–10 L/min. This configuration maintained post-filtration PCO_2 between 10–25 mmHg and achieved a CO_2 clearance of 44.5 mL/min, consistent with reported ranges of 35–75 mL/min [8,19].

The main challenge in prolonged $ECCO_2R$-CRRT is anticoagulation. The KDIGO guidelines caution against RCA in hypotension or severe liver disease, yet our patient required vasopressors throughout treatment [17]. Nevertheless, the LMWH + 4% citrate regimen was safe and effective: circuit lifespan averaged 65.67 hours, with no clinically significant bleeding and stable haemoglobin.

To our knowledge, this is the first report demonstrating the feasibility of RCA-based anticoagulation in CRRT-$ECCO_2R$ at a blood flow of 300 mL/min. This regimen addresses previous concerns about RCA safety in hypotensive patients and provides a practical option for centres without advanced ECMO capabilities. However, the single-case nature and loss to follow-up are limitations; larger studies are needed to validate these findings.

5. Conclusions

In CRRT-$ECCO_2R$ therapy, the anticoagulation regimen of LMWH + 4% citrate effectively maintained circuit patency (mean lifespan 65.67 hours) at a high flow rate of 300 mL/min, achieved a mean CO_2 clearance of 44.5 mL/min, and rapidly corrected refractory hypercapnia (mean $PaCO_2$ reduction 51.2 mmHg). No clinically significant bleeding occurred, and ionized calcium remained controllable. This protocol overcomes key limitations of conventional unfractionated heparin, validates the feasibility of RCA in high-flow $ECCO_2R$-CRRT, and offers a practical option for critically ill hypercapnic patients with bleeding risk.

Ethics statement

Consent was obtained from the patient's family for the treatment regimen and for publication of this case report. The study was conducted in accordance with the principles of the Declaration of Helsinki (version 2013, October; available at www.wma.net) and with Chinese laws regarding human-based research.

Author contributions

Qiongxing Bu designed the work. Qiongxing Bu, Yuejun Liu, and Wei Yang collected and analysed the data. Qiongxing Bu, Yuejun Liu, Wei Yang, Zhifeng Zhou, and Ling Zhang drafted and substantially revised the manuscript. All authors read and approved the final manuscript.

Funding

Enterprise-Commissioned Project Funding, West China Hospital of Sichuan University (Project No.: 339120022)

Disclosure statement

The authors declare no conflict of interest.

References

[1] Hepokoski M, Englert J, Baron R, et al., 2017, Ventilator-Induced Lung Injury Increases Expression of Endothelial Inflammatory Mediators in the Kidney. American Journal of Physiology Renal Physiology, 312(4): F654–F660.

[2] Romagnoli S, Ricci Z, Ronco C, 2016, Novel Extracorporeal Therapies for Combined Renal-Pulmonary Dysfunction. Seminars in Nephrology, 36(1): 71–77.

[3] Consales G, Zamidei L, Turani F, et al., 2022, Combined Renal-Pulmonary Extracorporeal Support with Low Blood Flow Techniques: A Retrospective Observational Study (CICERO Study). Blood Purification, 51(4): 299–308.

[4] Hu X, Zhang W, Jiang Y, et al., 2024, Impact of Extracorporeal Carbon Dioxide Removal Combined with Continuous Renal Replacement Therapy on Diaphragmatic Function in Patients with Acute Respiratory Distress Syndrome. Zhonghua Wei Zhong Bing Ji Jiu Yi Xue, 36(2): 147–151.

[5] Qian Z, He H, Wang Y, et al., 2024, Evaluation of CO2 Removal Rate of ECCO2R for a Renal Replacement Therapy Platform in an Experimental Setting. Artificial Organs, 48(6): 586–594.

[6] Combes A, Hajage D, Capellier G, et al., 2018, Extracorporeal Membrane Oxygenation for Severe Acute Respiratory Distress Syndrome. New England Journal of Medicine, 378(21): 1965–1975.

[7] Boyle A, Sklar M, McNamee J, et al., 2018, Extracorporeal Carbon Dioxide Removal for Lowering the Risk of Mechanical Ventilation: Research Questions and Clinical Potential for the Future. Lancet Respiratory Medicine, 6(11): 874–884.

[8] Godet T, Combes A, Zogheib E, et al., 2015, Novel CO2 Removal Device Driven by a Renal-Replacement System Without Hemofilter: A First Step Experimental Validation. Anaesthesia, Critical Care & Pain Medicine, 34(3): 135–140.

[9] Cappadona F, Costa E, Mallia L, et al., 2023, Extracorporeal Carbon Dioxide Removal: From Pathophysiology to Clinical Applications; Focus on Combined Continuous Renal Replacement Therapy. Biomedicines, 11(1): 142.

[10] Chen T, Sheng X, Zhang H, et al., 2024, Extracorporeal Carbon Dioxide Removal Combined with Continuous Renal Replacement Therapy in a Uremic Patient with Severe COVID-19. Zhonghua Nei Ke Za Zhi, 63(9): 889–892.

[11] Chen Y, Wang S, Huang J, et al., 2021, Application of Extracorporeal Carbon Dioxide Removal Combined with Continuous Blood Purification Therapy in ARDS With Hypercapnia in Patients with Critical COVID-19. Clinical Hemorheology and Microcirculation, 78(2): 199–207.

[12] Cappadona F, Costa E, Mallia L, et al., 2023, Extracorporeal Carbon Dioxide Removal: From Pathophysiology to Clinical Applications; Focus on Combined Continuous Renal Replacement Therapy. Biomedicines, 11(1): 142.

[13] Zhang W, Hu X, Yue L, et al., 2024, Effect of Extra Corporeal Reducing Pre-Load on Pulmonary Mechanical Power in Patients with Acute Respiratory Distress Syndrome. Zhonghua Wei Zhong Bing Ji Jiu Yi Xue, 36(12): 1244–1248.

[14] Liu S, Xu S, Yin L, et al., 2023, Management of Regional Citrate Anticoagulation for Continuous Renal Replacement Therapy: Guideline Recommendations from Chinese Emergency Medical Doctor Consensus. Military Medical Research, 10(1): 23.

[15] Rognoni C, Pohlmeier R, Tarricone R, 2025, Regional Citrate Anticoagulation Versus Systemic Heparin in Continuous Kidney Replacement Therapy: Examining the Role of Evidence in Health Technology Assessment. Advances in Therapy, 42(6): 2606–2638.

[16] Tonetti T, Zanella A, Pérez-Torres D, et al., 2023, Current Knowledge Gaps in Extracorporeal Respiratory Support. Intensive Care Medicine Experimental, 11(1): 77.

[17] Soliman N, 2012, Orphan Kidney Diseases. Nephron Clinical Practice, 120(4): c194–c199.

[18] Zhou Z, Liu C, Yang Y, et al., 2023, Anticoagulation Options for Continuous Renal Replacement Therapy in Critically Ill Patients: A Systematic Review and Network Meta-Analysis of Randomized Controlled Trials. Critical Care, 27(1): 222.

[19] Karagiannidis C, Kampe K, Sipmann F, et al., 2014, Veno-Venous Extracorporeal CO2 Removal for the Treatment of Severe Respiratory Acidosis: Pathophysiological and Technical Considerations. Critical Care, 18(3): R124.

Publisher's note

Bio-Byword Scientific Publishing remains neutral with regard to jurisdictional claims in published maps and institutional affiliations.